

One Day Surgery Times

Issue 1

Volume 2

February 2011

Editor:

Dr. T. Naresh Row

Board:

Dr. Paras Jain

Dr. T. Seema Row

Dr. Kishore Adyanthaya

Dr. Bharat Shah

Ms. Smita Khanna

A monthly publication of One Day Surgery India Private Limited

Rs. 10/-

www.one-daysurgeryindia.com

9th International Congress on Ambulatory Surgery is being held on:
8th to 11th May 2011 in **Copenhagen**, Denmark.

Please log on to www.iaascongress2011.org for further details.

From the Editors Desk:

Minor procedures in Day Care:

Cont.....:

In continuation with minor procedures that can be performed as OPD in a small set up, we will be touching on a very controversial issue, and that is: I & D for small abscesses under local anaesthesia. Very common and

an everyday presentation, Carbuncle, Finger nail abscesses, and 'boils' gone bigger.

They can occur anywhere in the body surface, but, the most common presentation is in the groin, abdominal fold, axilla and buttocks. Mind you, a clear diagnosis, so as to not confuse with cold abscesses of the neck and the inguinal region, and peri-anal abscesses should be made. This is necessary as the surgical, or rather, anaesthesia requirement is different.

Most of the abscesses presenting on the fingers and nails of the hand can be drained under Ring block.

Carbuncles are usually associated with diabetes, but, skin and sub-cutaneous abscesses are common presentations, especially in a tropical country like India, without diabetes also.

The Sebaceous gland/ Hair follicle gets infected by the most commonest gram positive organisms, Staphylococcus. The controversy is when to incise? Antibiotics, local applications, heat fomentation, work for some cases, but, a few need surgical intervention. Reason to incise: pain, fever, signs of inflammation. Surgically, any abscess in the body has to be drained, or nature will drain it, so we are taught. But, nature with all its good intentions, causes a lot of destruction of the surrounding tissues, like the overlying skin and the underlying fatty tissue. The abscesses 'burst' by eroding the sub-cute fat and the skin, presenting with multiple holes and then a big opening with irregular margins. Our skin is bestowed with millions of melanin pigments and these, as is with any inflammation, collect at the sight of infection, leading to ugly discoloration, which does not fade away with time. Therefore, a timely cut, will minimise the destruction and scar formation.

Once the decision is made to do an I & D, the choice on

anaesthesia is another controversial subject. Again, we are taught, that local anaesthesia does not work in inflamed areas and it is dangerous to inject in the effected area as it can cause spread of the infection to the surrounding non-infected areas. Well, this is true to a large extent. Keeping this in mind, we have found that certain modifications, like using a small caliber needle, like 27 G, and keeping clear of the inflamed region by at least 5 mm, and infiltrating in a fan wise manner, on all four quadrant, with a reasonable amount of anaesthetic agent, depending on the size and site of lesion, helps in providing local anaesthesia which is quite effective. Wait for a good 7 to 10 min. for the effect to achieve its maximum and then proceed with the surgery.

Cruciate incision and through curetting with irrigation of povidon iodine and hydrogen peroxide solution, followed by light packing, or hemostatic packing, is the standard to be followed. Care is taken in excising the necrotic skin and tissue. The recent trend is to minimize the skin excision.

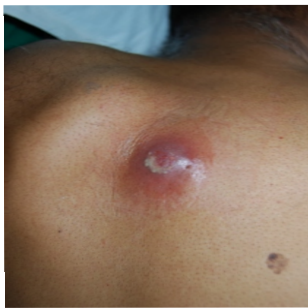Though local anaesthesia does not work 100% in an infected field, but, it definitely reduces the pain of surgery to a great extent. With experience, it is possible to do most I & D's under local anaesthesia as Day Surgery, avoiding GA, and hospitalisation.

The pack is to be removed after 48 hours in most cases, except if it gets very wet, then it can be changed earlier. Also, the trend is to pack lightly and not very tight in subsequent dressings. Allowing the wound to heal and reduce the pain of daily dressing. The need for follow-up dressing pack is to allow the gauze to act like a drain, absorbing necrotic fluid and pus that follows for a few days post drainage and keep the mouth of the wound open so that the granulation takes place from inside and the wound heals completely.

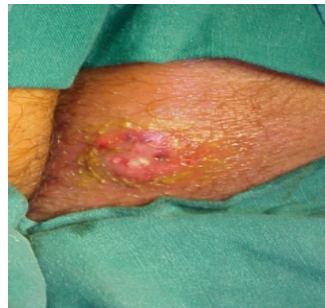Sometimes, there is a need to excise further slough from the wound during subsequent dressings, which can be easily done by carefully using a fine scissors. Alternatively, a few drops of local anaesthesia can be put in the wound and after a few min., Proceed.

Hydrogen peroxide burns, it should follow povidon iodine in the wound and that too, only a few drops. It helps by dislodging slough due to its bubbling effect & oxygen release.

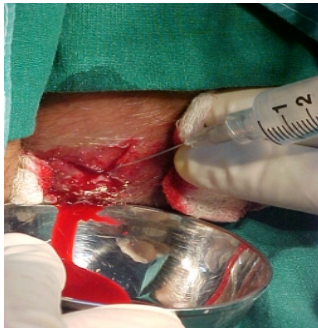Most small abscesses can be managed by this method, larger ones and in sensitive area require a short GA.



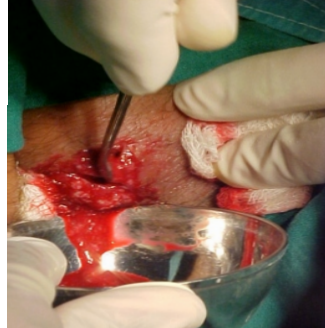Carbuncle-back



Necrotic skin



I & D under Local



Curetting

Surface to be anaesthetised is decided on the type of suture, but, usually, 1 cm around the cut skin should be adequate for fine suturing.

Simple sutures

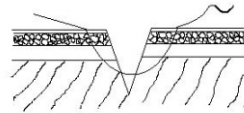


Fig. A

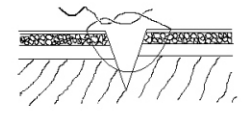


Fig. B

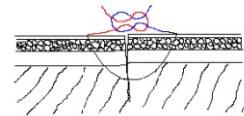


Fig. C

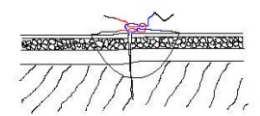


Fig. D

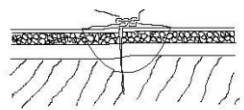


Fig. E

Fig. A to E depict different stages of simple suturing.

Simple sutures are ideal for thick skin, like that of the scalp, palms, sole and face. Where, the skin does not fold inwards.

Mattress Sutures

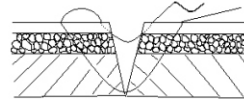


Fig. F

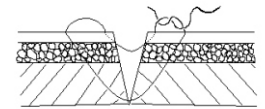


Fig. G

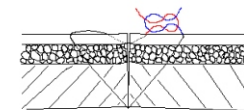


Fig. H

Fig. F to H depict Mattress sutures.

Mattress sutures are ideal for soft skin and deep wounds, where, inward folding of skin margins need to be prevented for better approximation.

- Dr. T. Naresh Row
President, The Indian Association of Day Surgery

CLW:


Clean Lacerated Wound, a very common affliction seen in our practice. If only skin and sub-cute tissue is involved, then it can be sutured under local anaesthesia as OPD in the clinic.

Two types of sutures are usually used: Simple and Mattress. Most commonly used suture material are Chromic Catgut, 3-0 or 4-0, with a small cutting needle, ideal for mucosal surface, like the lips. Advantage, these are absorbable and do not have to be removed.


Black Braided Silk or (Ethylon) Monofilament Polyamide non absorbable suture material, for direct skin sutures. Again, most commonly used would be 3-0 or 4-0 sutures on cutting needle.

All that is required is a small needle holder, 6" long and a suture cutting scissors.

The wound is cleaned with povidon iodine, local anaesthetic, in the form of 2% Lignocain HCL is injected along the margine of the wound from the inside, some prefer to inject from the outside of the wound, with a 27G needle. Wait for 5 to 7 min., Then proceed with suturing.



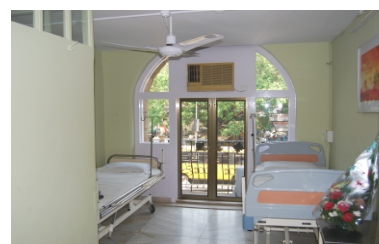
Surgery & discharge on same day for:
Hernia, Piles, Fistula, Fissure, Diabetic foot, Pilonidal sinus, Ingrown toe nail, Lipoma, Sebaceous cyst, Abscess, Circumscian, Vasectomy, D & C, Tubal Ligation, Diagnostic Lap; etc. (In selected cases)
Extended stay: Appendix, Gall stones, Hystrectomy, etc.



Other Surgeries related to: Paediatric, Urology, Plastic, ENT, Vascular. Chemotherapy & related treatment. (Please take prior appointment).

One Day Surgery Center
BABULNATH HOSPITAL
An exclusive Day Care Surgery Center with 24 hours nursing care & extended stay facility

15, Sadguru sadan, Opp. Babulnath Mandir, Babulnath Road, Mumbai-400 007. **Tel.:** 23674758, **Fax:** 2367 5221
E-mail: nareshrow@hotmail.com **Web:** www.one-daysurgeryindia.com



Patient's convenience and safety is our prime concern.