

One Day Surgery Times

Issue 1

Volume 3

February 2010

Editor:

Dr. T. Naresh Row

Board:

Dr. Paras Jain
Dr. T. Seema Row
Dr. Kishore Adyanthaya
Dr. Bharat Shah
Ms. Smita Khanna

A monthly publication of One Day Surgery India Private Limited

Rs. 10/-

www.one-daysurgeryindia.com



From the Editors Desk:

Anal Surgeries as Day Care:

Conti.....

Abscess:

One of the theories of peri-anal and ischio-rectal abscess formation is infection of the anal gland, which can lead to abscess formation and eventually a Fistula-in-ano, this is the 'Cryptoglandular' theory.

The perineum and the peri-anal area is a potentially infected area, with plenty of sub-cutaneous fat and loose tissue, it forms a rich source for any infective pathology to flourish. Most infections are due to E-Coli, Enterococcus or Bacteroides. We must keep in mind certain unusual or less common causes like: tuberculosis, squamous cell carcinoma, adenocarcinoma, actinomycosis, lymphogranuloma venereum, Crohn's disease, trauma, leukemia, and lymphoma.

Symptoms: Presentation are varied, as per the severity. The most common are: painful swelling in the peri-anal/anal region, unable to sit, difficulty in passing stools, pain is usually throbbing, with or without fever.

Types: Depending on the plane or site of presentation, most commonly, they are: Peri-anal, Ischio-rectal and Sub-Mucosal or Intra-muscular. Supra-levator or Pelvic abscess are not so common. In practice, mostly we see Perianal or Ischio-recta/anal type of presentation. Frequency is usually 60% for Peri-anal; 30% for Ischio-rectal; and 10% for the rest of the presentations.

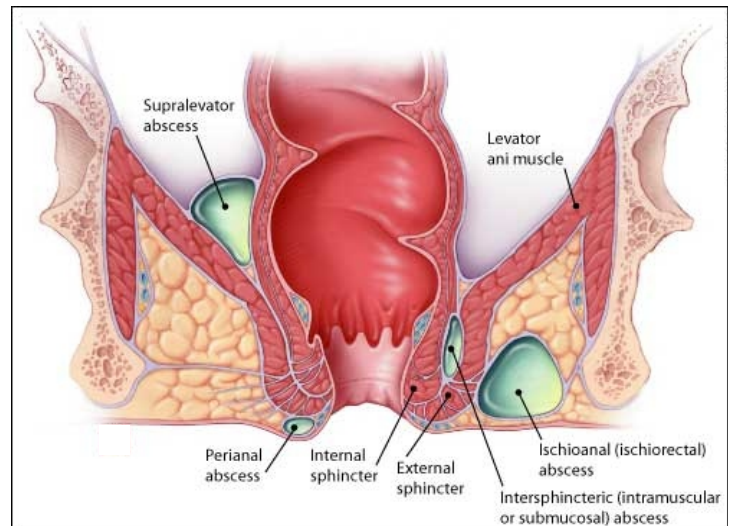
Management: Clinical examination consisting of inspection, palpation and if possible per-rectal examination, is usually required. Inspection will show you the swelling and its status, palpation should be gentle as it is very painful and if the patient does not allow, then can be left for later. But, state of induration, signs of inflammation, fluctuation, can be easily assessed without hurting the patient. Per-rectal examination, though important,

should be left for more expert hands, as this is very painful. Antibiotics, painkillers, including Seitz bath and stool softners should be started immediately.

Remember, once there is definite pus formation, it usually always requires drainage, or nature will drain it. To consider that strong antibiotics will suppress it, is a misconception. This may happen in the early stage, when there is just induration and oedema and minimal liquification of fat tissue. The difference with bursting of the abscess on its own is that it is messy, causes a lot of skin damage resulting in skin loss and big cavity, requiring longer time to heal and severe scarring. Where as, if it is surgically drained, then, the skin damage can be controlled, resulting in early healing with a decent scar.

Investigations: usually pertaining to surgery. WBC counts may be high in certain cases. USG / CT-Scan are of use in cases where there is a diagnostic dilemma or in Intra-pelvic type of abscesses.

In certain cases, for Intra-sphinctric abscesses, digital examination gives information in the form of induration or boggy, but, if in doubt, Rectal USG can be helpful.



Anaesthesia: most of the surgeries can be easily performed under a short GA, but, in expert hands, local and sedation can allow faster recovery. Other modalities are Spinal, Caudal and General anaesthesia.

Surgery: simple I & D is all that is required at the point of least resistance, that is, most soft area. Classical 'Cruciate' incision, with drainage and curettage, followed by irrigation with Povidon-Iodine and Hydrogen peroxide and packing with gauze or bandage roll, is required. Packing is necessary for homeostasis.

Post-operative care: This includes, antibiotics, painkillers, stool softeners and most importantly, Hot Seitz bath.

The diet should be normal, with high fiber.

The pack is usually removed after 2 days. This is ideally done after a Seitz bath, so that a wet pack is easy to remove. First dressing can be sometime painful, therefore, a painkiller taken before visiting the doctor is helpful. Once the pack is out, gentle cleaning with Povidon-Iodine and few drops of Hydrogen peroxide and loose packing, is sufficient. Irrigation of wound may be required in larger cavities. This type of dressing can be easily carried out at your clinic till the wound heals completely from inside and only the skin surface remains, superficially. Then, simple metronidazole or Povidon Iodine ointment dressing is sufficient till the wound completely closes.

Remember: two third of all peri-anal and ischio-rectal abscesses are precursors of a Fistula-in-ano. Therefore, it is mandatory to prepare the patient's mind during the treatment of the abscess, as well as, follow-up for 3 months, post drainage, for any fistula.

Case 1: A young girl of 14 yrs., Presented with complaints of painful swelling in the peri-anal region with fever since 8 days. She had difficulty in sitting and defecation. She correlated the swelling with an injury while playing in school and did not inform her parents for 2 days. Later, she was taken to her family physician and medication was prescribed to reduce the pain and fever. In spite of 5 days of antibiotics and painkillers, fever and pain, in fact, increased. On examining her, an angry looking badly inflamed swelling with extensive induration greeted me. Extending on both sides of the poor girls vulva, perineum and buttocks, more on one side as it was pointing towards that side.

Surgery was performed the next day under short GA. A cruciate incision released almost a liter of foul smelling purulent material. Examination revealed an 'H' shaped cavity involving the areas described above, with the anus in the center. Curettage, irrigation and packing was done. Seitz bath and dressings continued for a month.

She came back after 3 months with a fistula-in-ano, an external opening at the incision site and internal opening at 12 O'clock position.

Case 2: 30 yrs. Old female patient, presented with a painful swelling in the per--anal region since 11 days. Not responding to antibiotics and pain killers. Examination revealed an are of a size of a large orange with induration up to the anus and fluctuation in the center. I & D was done, followed by curettage and packing. Dressings followed for a month. 3 months follow-up showed a nicely healed scar with no evidence of a fistula.

Remember: Local examination, Drainage of pus, antibiotic coverage for anaerobic bacteria, is must in all such cases.



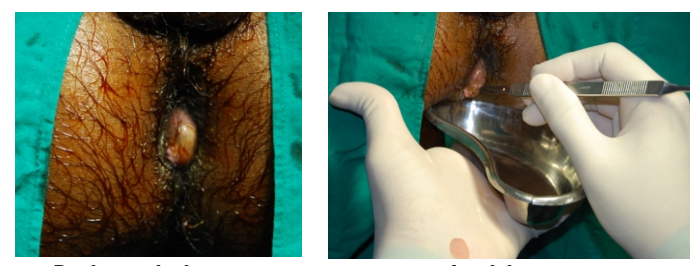
Surgery & discharge on same day for:
Hernia, Piles, Fistula, Fissure, Diabetic foot, Pilonidal sinus, Ingrown toe nail, Lipoma, Sebaceous cyst, Abscess, Circumcision, Vasectomy, D & C, Tubal Ligation, Diagnostic Lap; etc. (In selected cases)

Extended stay: Appendix, Gall stones, Hystrectomy, etc.



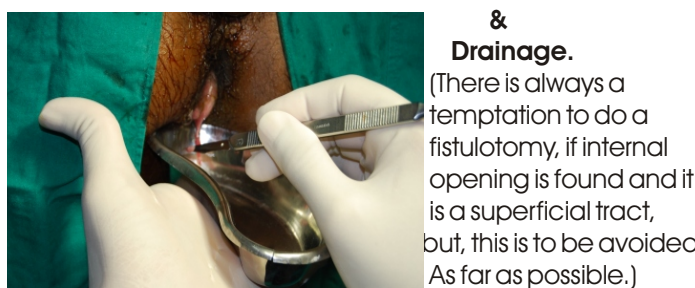
UKAS
ACCREDITED
95A
ISO 9001:2008 CERTIFIED ORGANISATION

Other Surgeries related to: Paediatric, Urology, Plastic, ENT, Vascular. Chemotherapy & related treatment. (Please take prior appointment).



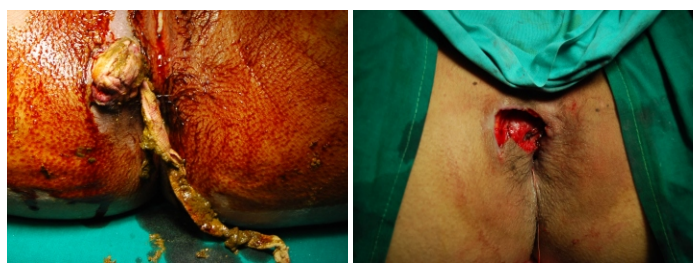
Peri-anal abscess

Incision.....



& Drainage.

(There is always a temptation to do a fistulotomy, if internal opening is found and it is a superficial tract, but, this is to be avoided As far as possible.)



Packing

Abscess cavity

To be continued.....

- Dr. T. Naresh Row



One Day Surgery Center
BABULNATH HOSPITAL

An exclusive Day Care Surgery Center with 24 hours nursing care & extended stay facility

15, Sadguru sadan, Opp. Babulnath Mandir, Babulnath Road, Mumbai-400 007. Tel.: 23674758, Fax: 2367 5221
E-mail: nareshrow@hotmail.com Web: www.one-daysurgeryindia.com

Patient's convenience and safety is our prime concern.