

# One Day Surgery Times

Volume 1 no. 5

Issue: August 2013

## Editor:

Dr. T. Naresh Row

## Board:

Dr. Paras Jain  
Dr. T. Seema Row  
Dr. Kishore Adyanthaya  
Dr. Bharat Shah  
Ms. Smita Khanna

A monthly publication of **One Day Surgery India Private Limited** Free for Distribution

[www.one-daysurgeryindia.com](http://www.one-daysurgeryindia.com)

\* 7th National Conference on Day Surgery: **ADSCON 2014**, will be held in Chennai on 18th & 19th April. Please mark the dates and look for details on [www.daysurgeryindia.org](http://www.daysurgeryindia.org) soon.

\* **11th IAAS Congress** will be held in Barcelona, Spain, from 8th to 11h May, 2015.

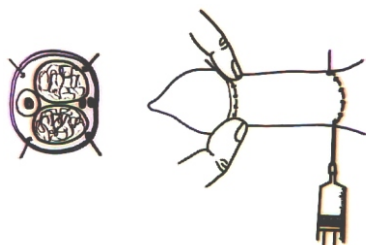


## From the Editors Desk:

### General Surgery under Local anaesthesia: (continued...)

Testicular biopsy is usually performed under local infiltrative block, sometimes under cord block.

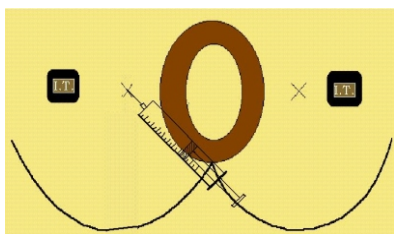
Cases of Pyocoele, Gangrenous skin of the scrotum, usually seen in diabetic infections or Fournier's gangrene, can be performed under Cord/Scrotal blocks, but only in selected cases. Haemangiomas of the scrotum can also be done under this block.



Penile block is useful for Circumcision. As this is an end artery, anaesthetic solution of lignocaine and bupivacaine, without adrenaline should be used. Injection is given at the penile base or mid-shaft, on both sides and then in the skin on the dorsal and ventral surface. Meatotomy, Meatoplasty, small

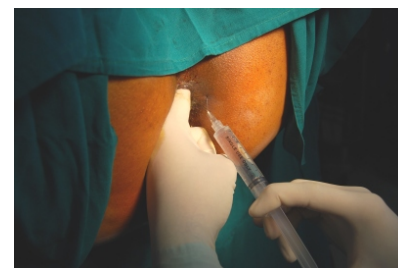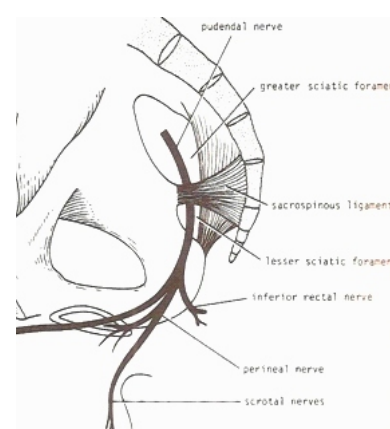
Hypospadias correction, excision of Plaque are some of the surgeries that can be performed under this block.

Pudendal block is used for all types of anal and peri-anal surgeries.



This block requires some practice and patience. Anatomically, when a patient is lying in the lithotomy position, with both legs up in the stirrup, surgeon has to be comfortably sitting facing the patient's buttocks. Anaesthetic solution of 2% lignocaine with adrenaline and 0.5% bupivacaine, is preferred. A well lubricated finger is inserted in the anus, (with patient under sedation, as this is a sensitive area), the ischial spine is felt, it is deep, along the lateral rectal wall, in the direction of the hip joint, this is where the Pudendal nerve and the vessels travel. On the skin, a spot mid way between the anal verge

and the ischial tuberosity is selected and with the finger as a guide, the needle is directed towards the ischial spine. Near and around the ischial spine, the anaesthetic solution is injected after aspiration and keeping in mind all the precautions of fan-wise injection and not more than 5 ml as bolus in one spot, upto 10 ml is injected in one side. The needle is angled towards the hip joint with the patient remaining in the lithotomy position. Similar injection is given on the other side to complete the block. Giving a complete relaxation of the anal canal/sphincter. In cases of painful anal conditions, 2% lignocaine jelly should be used to avoid unnecessary pain of inserting the guiding finger.



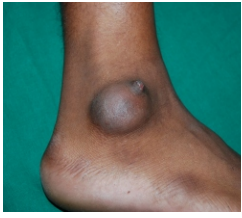Similarly, by feeling the anal sphincter all around, 5 ml of anaesthetic solution, can be injected at all the four quadrants, into and around the sphincter to achieve a Ring block. But, the relaxation is not as good as the Pudendal block.

Once the effect of anaesthesia is reached after 5 to 10 min, we can see the anal sphincter relaxing and can proceed with the surgical procedure. Usually, sedation is required while giving this injection.

Anal surgeries like Haemorrhoidectomy, Fistulectomy/Fistulotomy, Lateral sphincterectomy, Fissurectomy, Rectal polyp excision, anal sphincter stretching, drainage of perianal abscesses, can be comfortably performed under Pudendal block. The alternative to this type of anaesthesia is Caudal block, Saddle block, Spinal anaesthesia or GA.

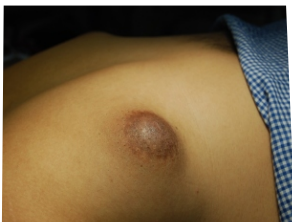There is a learning curve, like in all types of blocks, but, once you have the experience, then it has evident advantages.

A word on Field block. Infiltrative anaesthesia is such a wonderful thing, that, once you get used to it, you will probably want to do most surgeries under LA.

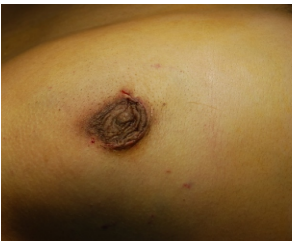

Excision of Sebaceous cyst and Corn, CLW suturing, Lipoma excision, are common and superficial skin afflictions. But, surgeries of Gynaecomastia, Breast lump in female patients, certain deep Lymphnode excision biopsies and excision of Bursa, can also be performed under this type of anaesthesia. Though, these patients definitely require sedation.

Particular care is taken when injecting around the Lymph nodes as they are associated with the body's vascular structures. Inadvertent injection into the adjoining vessels can lead to fatalities. Deeper Lymph nodes, for example, in the sub-mandibular region, are under the Sterno-Cleido-Mastoid muscle, and can be accessed only by dividing this muscle and later suturing it. Careful and slow dissection becomes a necessity, to protect the surrounding structures.



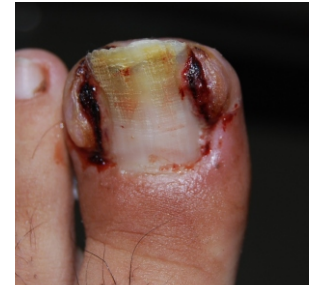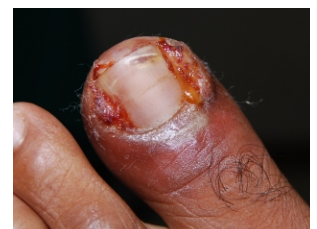Gynaecomastia surgeries require a four quadrant infiltration and into the skin at the sub-areolar line. The areolar flap is created by taking the incision in semi-circular manner and the underlying fatty breast tissue is excised in a circumferential manner so as to achieve a uniform, flat contour. Post haemostasis, suturing is done only with sub-cuticular sutures.



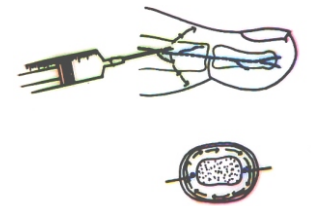
Similarly, breast lumps of different sizes can be easily removed by infra areolar incision, or if away from the areola, then, on the bump itself.

Ingrown toe nail, is another very common surgery performed as OPD, under LA. This is a surgery and disease, which is best prevented, otherwise, can become a recurrent nuisance. Abscesses and overgrown granulation tissue needs to be excised. It really does not matter if you remove the complete nail

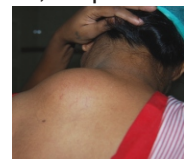Or just the offending strip of nail. Important is the removal of the infected and affected tissue. Sometimes, it becomes necessary to suture the gap so as to hasten healing and prevent ingrowth. Remember, nail is important for the protection of the sensitive tip of the toes, so it will and should grow back. Nail care is to be taken to prevent it from growing back in. Usually, small pellets of cotton, size of a grain of rice, can be inserted under the corner of the nail, as it grows, so as to prevent it from growing in, then the edges can be cut.



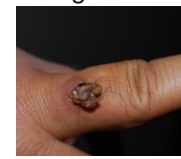
Toes being end arteries, LA should be without adrenaline. The nerve supply is from the sides of the finger/toe, therefore, the injection is on both sides, at the base of the toe. To take effect, you may require a waiting period of 10 min after injection. Also, this is very common in the school going children probably due to narrow shoes or sports injury. Also, during surgery, they should be explained that they will feel that something is being done, but no pain will be felt. Apprehension may make them uncooperative, reassurance is a must.



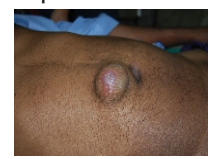
The following pictures speak for themselves. All I need to repeat is that, the possibilities of surgeries under LA is phenomenal.



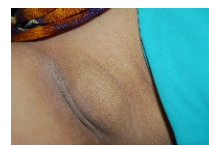Lipoma: back



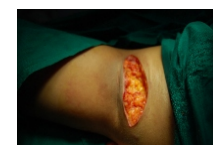Granuloma: finger



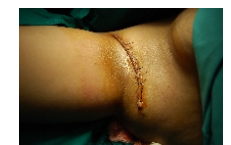Sebaceous cyst



Axillary Lipoma




Excised



Sutured

- Dr. T. Naresh Row (continued.....)

**Surgery & discharge on same day for:**  
Hernia, Piles, Fistula, Fissure, Diabetic foot, Pilonidal sinus, Ingrown toe nail, Lipoma, Sebaceous cyst, Abscess, Circumcision, Vasectomy, D & C, Tubal Ligation, Diagnostic Lap; etc. (In selected cases)  
**Extended stay:** Appendix, Gall stones, Hysterectomy, etc.




**Other Surgeries related to:** Paediatric, Urology, Plastic, ENT, Vascular. Chemotherapy & related treatment. (Please take prior appointment).

## One Day Surgery Center BABULNATH HOSPITAL

An exclusive Day Care Surgery Center with 24 hours nursing care & extended stay facility

15, Sadguru sadan, Opp. Babulnath Mandir, Babulnath Road, Mumbai-400 007. Tel.: 23674758, Fax: 2367 5221

E-mail: nareshrow@hotmail.com Web: www.one-daysurgeryindia.com



**Patient's convenience and safety is our prime concern.**

**Printed by:** Dr. T. Naresh Row, **Published by:** Dr. T. Naresh Row, **Owned by:** Dr. T. Naresh Row, **Printed at:** Gemini Printing Press, 33/A, Kanbai wadi, Khadilkar Road, C.P. Tank, 1st fl., Opp. Pooja Cards, Mumbai-400 004. **Published at** One Day Surgery Center, 15, Sadguru sadan, Babulnath Road, Mumbai-400 007. **Editor:** Dr. T. Naresh Row